

ORIGINAL ARTICLE

## Endoscopic treatment of anastomotic biliary complications after liver transplantation using removable, covered, self-expandable metallic stents

CAROLA HAAPAMÄKI, MARIANNE UDD, JORMA HALTTUNEN, OUTI LINDSTRÖM, HEIKKI MÄKISALO & LEENA KYLÄNPÄÄ

Department of Gastrointestinal Surgery, Helsinki University Central Hospital, Helsinki, Finland

### Abstract

**Objective.** Anastomotic bile duct complications after liver transplantation (LT) have been treated endoscopically by dilation and plastic tube stenting, with the stent therapy having moved toward using covered, self-expandable metallic stents (cSEMS) in recent years. The aim of this study was to analyze therapy outcome of post-LT anastomotic complications using cSEMS. **Material and methods.** Seventeen post-LT patients had 29 cSEMS (Allium stent,  $n = 23$ ; Wallstent<sup>®</sup>,  $n = 4$ ; Micro-Tech,  $n = 2$ ) placed during endoscopic retrograde cholangiopancreatography (ERCP). The fully covered stents (Allium, Micro-Tech) were placed entirely inside the common bile duct. Data were collected and analyzed in a retrospective manner. **Results.** These 17 patients had 19 stent treatment periods. Resolution was eventually established in all patients. There were four (14%) stent migrations. Pancreatitis was seen after one ERCP procedure, whereas five cases of cholangitis were seen. **Conclusion.** Treatment of post-LT anastomotic complications with cSEMS seems to be both safe and efficient. Further assessment regarding indications, stent types and stenting time is needed.

**Key Words:** cSEMS, ERCP, liver transplantation, metallic stent

### Introduction

Biliary complications after liver transplantation (LT) occur in 5–34% of cases [1]. The most common complication by far is anastomotic stricture, accounting for approximately 40% of all biliary complications. Other complications include biliary leakage, multiple ischemic strictures, sludge, stones, sphincter of Oddi dysfunction, mucocoeles and hemobilia [2]. Furthermore, biliary complications after living donor LTs are more frequent, as their incidence is 28–32% compared to 5–15% after deceased donor LTs [2]. Traditionally, treatment options in biliary complications have been surgery or percutaneous transhepatic cholangiography (PTC) with balloon dilation. Over the past 15–20 years, however, endoscopic therapy has been advocated as the first-line treatment choice for

strictures and leaks. In cases of anastomotic complications after LT with choledocho-choledochotomy (CC) reconstruction, treatment has been dilation and application of plastic stents with endoscopic retrograde cholangiopancreatography (ERCP). The success rate has been 70–80% [2]. However, metallic stents are standard therapy in malignant strictures. In recent years there have been reports of using uncovered, partially covered and fully covered metallic stents for benign biliary strictures [3–7]. The feasibility of using metallic stents both in post-LT biliary conditions and generally in benign biliary conditions is still unclear.

The aim of this study was to analyze the therapy outcome of post-LT anastomotic biliary stricture or leakage using removable partly and fully covered self-expandable metallic stents (cSEMS).

Correspondence: Jorma Halttunen, PhD, Department of Gastrointestinal Surgery, Meilahti Hospital, Endoscopy unit, PL 340, 00029 HUS, Helsinki, Finland. Tel: +358504270635. Fax: +358947174688. E-mail: jorma.halttunen@hus.fi

(Received 29 August 2011; revised 23 October 2011; accepted 6 November 2011)

ISSN 0036-5521 print/ISSN 1502-7708 online © 2012 Informa Healthcare  
DOI: 10.3109/00365521.2011.639082

## Methods

### Patients

From 10 March 2008 to 5 May 2010, 17 patients had cSEMS placed during ERCP. Seven (41%) of the patients were male. The median age at the time of the first stent placement was 40 years, with a range of 18–61 years. One patient received a cadaveric, reduced liver at the age of 16, and the remaining 16 patients received full size LTs from cadaveric donors between the years 1999 and 2010. The indications for liver transplantation were acute or subacute liver failure in six patients, alcohol cirrhosis in five, Wilson's disease in two patients and non-alcoholic steatohepatitis/autoimmune hepatitis, primary biliary cirrhosis and autoimmune hepatitis/primary sclerosing cholangitis in one patient respectively. One patient had a re-LT due to chronic rejection, having had the first transplantation for treatment of Budd-Chiari syndrome. The vast majority, that is 12 patients, had their bile duct complication diagnosed during the first year after the transplantation, and the remaining five complications were diagnosed 1.8–10 years from the LT. Indication for the procedure was anastomotic stricture in 16 patients and bile leakage in one. All patients were administered ursodeoxycholic acid.

**General facts.** A single-center experience comprising 17 patients and 19 stent treatment periods is presented. Data were collected in a retrospective manner from patient charts and cholangiograms. In our country of 5.4 million inhabitants, transplantation surgery is centralized to Helsinki University Hospital. Thus, all major complications are also treated there, including post-LT biliary complications. Before centralizing all LT-related ERCPs to our endoscopy unit in the beginning of 2008, biliary strictures were treated in a different unit using plastic stents. Therefore, five patients had undergone ERCP with single diagnostic plastic stents prior to treatment in our unit. The patients included in the study were transplanted between January 1999 and March 2010. During that period, altogether 368 adult LTs were performed with CC anastomosis. Of these patients 15.8% were treated for a biliary complication and 27.6% of them by using cSEMS. Since March 2008, all anastomotic stent therapies were carried out using cSEMS only.

Inclusion criteria were (1) previous LT with CC-reconstruction and (2) postoperative anastomotic biliary complication.

**Technique.** All procedures were performed under conscious sedation managed by an anesthesiologist.

Primarily, a sphincterotome with a guide wire was used for cannulation. In cases of a native papilla, a sphincterotomy was performed. The location and length of the anastomotic stricture and possible leakage were visualized using a guide wire balloon and contrast media. Allium stents (Allium, Caesarea Ind. Park, Caesarea, Israel), fully covered by a novel polymeric material preventing tissue ingrowth and sludge occlusion, were used in all patients but one. This stent is made of a super-elastic nitinol alloy. Both anchored and, in one patient only, unanchored models were used. The stents used were 6, 8 or 10 cm long, expanding to a 10 mm diameter. One patient had her Allium stent replaced by a custom made, fully covered, 4 cm long Micro-Tech (Micro-Tech, Nanjing, China) cSEMS, and one patient was exclusively treated with a custom made, 3 cm long Micro-Tech stent. These two stents were chosen in order to acquire experience of short stents in post-LT, anastomotic strictures. Also, four 6–8 cm long, partly covered Wallstent® (Boston Scientific Corp., Boston, MA, USA) cSEMS were used in three different stenting entities. Two of them were used in two consecutive ERCP procedures, adding the second stent partly into the first one in order to be able to remove it as it had migrated inside the common bile duct (CBD). Except for the Wallstent, all other stents were placed entirely inside the CBD, leaving only the anchor outside the papilla (Figure 1, Figure 2A–C).

As the use of cSEMS was a new technique in our clinic, several patients, with emphasis on early stenting entities, had their cSEMS routinely changed three to four months after deploying the stent. In addition,

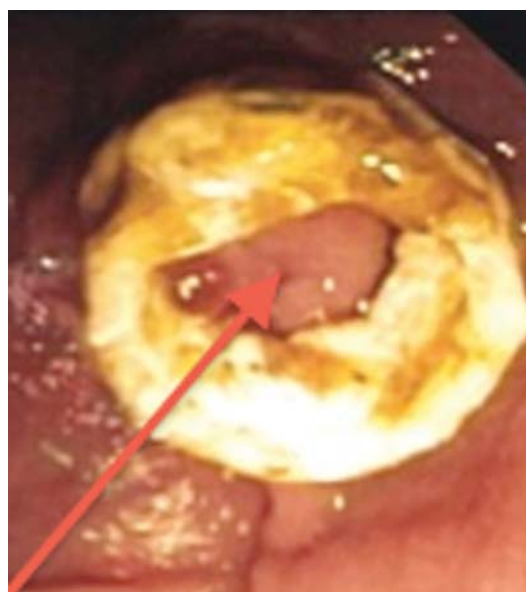

Figure 1. Endoscopic view of an Allium stent anchor in the duodenum. The papilla is marked by an arrow.

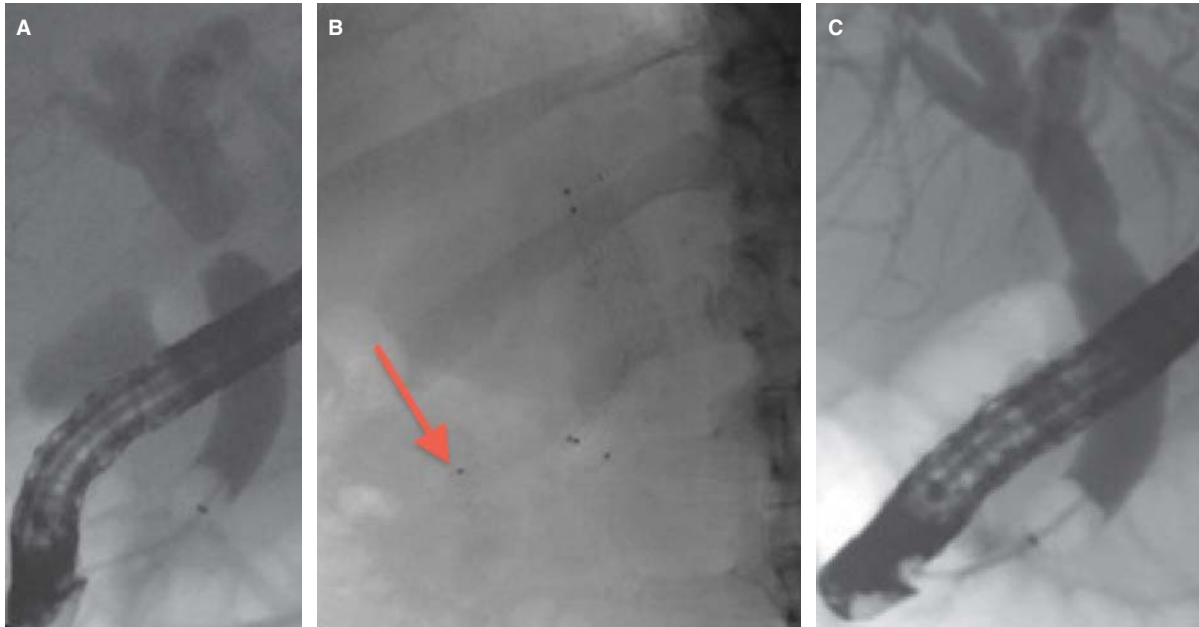


Figure 2. (A) Fluoroscopic cholangiography picture showing an anastomotic stricture in a liver transplanted patient. (B) Fluoroscopic picture of a fully covered Allium stent placed over the stricture in the patient in Figure 2A. The arrow points at the anchor. (C) Fluoroscopic cholangiography picture of the patient in Figure 2A after removal of the stent.

there were ERCP procedures to check the stent three months from deployment without changing or removing it.

As LT patients in Finland live all over the country, transplant surgeons often prefer having ERCP procedures performed at the time of otherwise scheduled appointments. This minimizes hospital visits and traveling, although the timing might not be in accordance with the endoscopists' recommendations for stent procedures. This arrangement partially explains the great variations in stenting time. Primarily a stenting time of six months was the intended goal.

*Follow-up.* The definition of post-ERCP pancreatitis and the grading of its severity were based on consensus criteria [8]. After the stent was removed and a stricture or leakage resolution was established, patients were clinically evaluated in the frame of routine post-LT controls. Furthermore, if needed, check-ups were arranged on demand.

*Statistics.* The statistics of the results are given in median and range.

## Results

### Procedures

These 17 patients treated with cSEMS had 19 stent treatment periods [Figure 3]. Stricture or biliary

leakage resolution was eventually established in all patients, even though two patients were re-treated because of recurrence. Altogether 58 ERCPs were performed, with a median of three procedures (2–6) to each treatment entity. A cSEMS was placed during 29 ERCP procedures; prior dilation to 6, 8 or 10 mm was performed 19 times. Seven ERCP procedures were performed to check the stent and two patients had a planned ERCP to ensure there was no stricture recurrence. The median number of cSEMS for each patient was two, ranging from one to four. Eight (47%) patients were treated with a single stent. Six patients had their stent exchanged three to four months from initial placement. All patients had a fall in their liver function tests as a result of stent therapy.

The sole leakage patient with the leakage ongoing after the first stent treatment received a second stent put partly inside the first one to cover the leak. Although the leakage resolved, the patient still suffered from cholangitis episodes. She apparently had multiple ischemic hilar and intrahepatic strictures as well, and was retransplanted after several attempts of bile duct dilation and plastic tube stenting. The follow-up of this patient was 8.7 months.

### Stenting time and follow-up

The stenting time was 6.8 months (0.9–10.1). The longest time of a single stent that remained *in situ* was

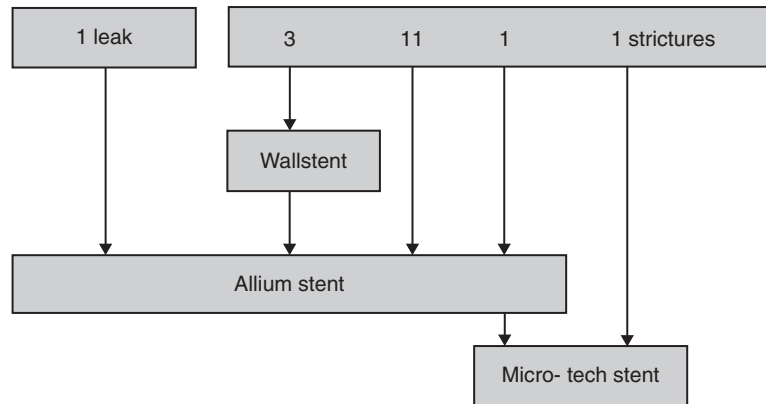


Figure 3. Division of the stents used.

9 months, and it was removed without difficulty. The follow-up after stent removal was 21.7 months (6.6–32.0). At follow-up, liver function tests remained on the level achieved after successful stent therapy.

#### *Drawbacks and complications*

Stent migration was seen in four occasions; three of them were related to use of a Wallstent stent. One of these stents could not be detected on abdominal fluoroscopy at all, denoting a complete migration. The Allium stent migrated just below the stricture once, and it was replaced by a custom made Micro-Tech stent. There were two stricture recurrences, one of which appeared 2.1 months after the initial resolution, following use of two Wallstent cSEMS. The recurrences were successfully treated using an Allium cSEMS. Complications were seen in six patients related to nine (15.5%) ERCP procedures. Fever, interpreted as cholangitis, was seen five times (8.6%). The Allium anchor snapped twice, but caused no difficulties while removing the stent. One Allium stent came out as a metal filament, leaving the cover in the CBD. The cover was removed with a FlowerBasket device (Olympus Medical Systems Tokyo, Japan). The recovery was complicated by bacteremia, which was successfully treated with antimicrobial drugs. This stent had remained for six months prior to removal. There was pancreatitis after one (1.7%) ERCP procedure. This pancreatitis was superimposed on cholangitis and was therefore regarded as mild although the postprocedural hospital stay was clearly prolonged. One patient presented with hematemesis two days after stent deployment, and a duodenoscopy was performed. A red spot found at the sphincterotomy site was treated with a heat probe. There were no deaths.

#### **Discussion**

The outcome of these biliary strictures and leaks treated with cSEMS was fair. Eventual resolution was reached in all patients, compared to recent reports, where anastomotic bile duct complications after LT with CC reconstruction were treated with maximal plastic stent therapy, with success rates of 87–94% [1,9,10]. The only recurrence related to an intracholedochal, fully covered SEMS was probably a consequence of too short a stenting time due to clinical misjudgment of the stricture site.

To our knowledge, there are no previous reports regarding cSEMS placed entirely inside the CBD, a technique that might overcome the cSEMS-connected issue of migration. The feasibility of metal stents in benign biliary diseases is unclear, and until recent years deployment of plastic stents during therapeutic ERCP was the treatment of choice. Uncovered metal stents have been placed in benign biliary strictures (also including other strictures than LT related), with limited long-term efficacy [3]. They are associated with epithelial hyperplasia affecting long-term stent patency. The embedding of the stent into the bile duct, in turn makes removal difficult or impossible. Results from treatment using removable cSEMSs in benign biliary strictures have been encouraging [4–7]. However, covered metal stents have been associated with a high rate of migration. In our earlier experience, the Allium stent had a high migration rate when placed across the papilla. Therefore later, during the study period, it was placed entirely inside the CBD.

The drawback of using plastic stents is the need of replacement every 3–6 months. In 2001, Costamagna et al. reported a successful use of multiple plastic stents in benign choledochal strictures with additive stent placement in consecutive ERCP sessions [11]. Tabibian et al. reported a 94% success rate when

applying this method in post-LT, anastomotic strictures [1]. In that study, each patient had a mean of three ERCPs, varying from 2 to 7. The average endoscopic treatment lasted 15 months. In our material, the number of ERCPs in each treatment entity varied from 2 to 6, with a median of 3 ERCPs. This quite high number of procedures is explained by the introduction of a new technique. It was not known with certainty for how long the cover material would stay intact and for how long the stent could be retained and still could remain removable. Therefore, the early stents were changed, and later checked, at three months from the initial procedure.

In liver transplant patients there are anatomic alterations affecting endoscopic treatment. The bile duct is longer than in non-transplanted patients, requiring a longer stent in cases where the stent has to reach the duodenum in order to be removable. The gallbladder of the transplant is always removed when present, entailing no concern of cystic duct occlusion as covered stents are used.

As fully covered, expandable metallic stents are more expensive than plastic ones, the potential benefits should be discussed. These stents reach a diameter of 10 mm, which equals seven plastic 10 Fr stents, resembling the principle of maximal stent therapy. The covering enables stent removal which, on the other hand, has been related to stent migration. One might overcome this problem using anchored stents, which are placed entirely inside the CBD. An intracholedochal stent is furthermore not occluding the orifice of the pancreatic duct, reducing the risk of pancreatitis [12]. In this material, we had only one (1.7%) patient suffering from post-ERCP pancreatitis. Sphincterotomy is not necessary prior to metal stent deployment (even though sphincterotomy was performed in every case in this series). Hence the risk of ascending cholangitis might be smaller, which could be considered especially beneficial in patients with a transplanted liver. Other sphincterotomy-related complications are bleeding, pancreatitis and perforation [13].

It is not known for how long the stent should and could be kept in place to avoid recurrences. According to studies using plastic stents, a one-year stenting time might be optimal [1,14]. The method implies that the last stenting period with the maximum number of stents is three months. We thought that a six-month stenting time corresponding to seven plastic stents would be sufficient.

#### *Future stents*

Clearly the goal of treatment using cSEMS will be a two-stage, deployment-removal protocol. The

limiting factor for the length of the stenting time is the cover of the stent. In our study all stents were removed with the cover intact, in one case after nine months. Now there are stents available, for example Wallflex<sup>®</sup> from Boston, with a guaranteed cover intactness of one year. Cost benefit is not an important issue anymore as one cSEMS replaces multiple plastic stents, diminishing stent exchanges, too.

A consideration whether removable stents damage the choledochal epithelium has been raised. Although some damage is probable, its clinical importance is unclear. Anastomotic strictures are short, and therefore shorter stents could be used in order to lessen the extent of possible epithelial damage. In our material we tested two short, 3 cm and 4 cm long, intracholedochal, custom made cSEMS with promising outcomes. Intracholedochal stents need a system for removal, though for example an anchor or a purse string suture dangling in the duodenum.

In the future bioabsorbable, self-degraded stents, so far tested in animal models only, might overcome the issue of epithelial damage and also make single intervention treatment possible [15–17]. On the other hand, it is not yet known whether debris after degradation will cause stone formation or other complications.

#### **Conclusion**

Treatment of post-LT anastomotic complications using cSEMS, especially entirely intracholedochally placed cSEMS, seems to be both safe and efficient. Further assessment regarding indications, stent types and stenting time is needed.

**Declaration of interests:** The authors have no conflicts of interest or financial ties to disclose.

#### **References**

- [1] Tabibian JH, Asham EH, Han S, Saab S, Tong MJ, Goldstein L, et al. Endoscopic treatment of postorthotopic liver transplantation anastomotic biliary strictures with maximal stent therapy (with video). *Gastrointest Endosc* 2010; 71:505–12.
- [2] Williams ED, Draganov PV. Endoscopic management of biliary strictures after liver transplantation. *World J Gastroenterol* 2009;15:3725–33.
- [3] van Boeckel PG, Vleggaar FP, Siersema PD. Plastic or metal stents for benign extrahepatic biliary strictures: a systematic review. *BMC Gastroenterol* 2009;9:96.
- [4] Vandenbroucke F, Plasse M, Dagenais M, Lapointe R, Letourneau R, Roy A. Treatment of post liver transplantation bile duct stricture with self-expandable metallic stent. *HPB (Oxford)* 2006;8:202–5.

- [5] Wang AY, Ellen K, Berg CL, Schmitt TM, Kahaleh M. Fully covered self-expandable metallic stents in the management of complex biliary leaks: preliminary data - a case series. *Endoscopy* 2009;41:781-6.
- [6] Traina M, Tarantino I, Barresi L, Volpes R, Gruttadauria S, Petridis I, et al. Efficacy and safety of fully covered self-expandable metallic stents in biliary complications after liver transplantation: A preliminary study. *Liver Transpl* 2009;15:1493-8.
- [7] Kahaleh M, Behm B, Clarke BW, Brock A, Shami VM, De La Rue SA, et al. Temporary placement of covered self-expandable metal stents in benign biliary strictures: A new paradigm? (with video). *Gastrointest Endosc* 2008;67:446-54.
- [8] Cotton PB, Lehman G, Vennes J, Geenen JE, Russel RC, Meyers WC, et al. Endoscopic sphincterotomy complications and their management: an attempt at consensus. *Gastrointest Endosc* 1991;37:383-93.
- [9] Pasha SF, Harrison ME, Das A, Nguyen CC, Vargas HE, Balan V, et al. Endoscopic treatment of anastomotic biliary strictures after deceased donor liver transplantation: outcomes after maximal stent therapy. *Gastrointest Endosc* 2007;66:44-51.
- [10] Morelli G, Fazel A, Judah J, Pan JJ, Forsmark C, Draganov P. Rapid-sequence endoscopic management of posttransplant anastomotic biliary strictures. *Gastrointest Endosc* 2008;67:879-85.
- [11] Costamagna G, Pandolfi M, Mutignani M, Spada C, Perri V. Long-term results of endoscopic management of postoperative bile duct strictures with increasing numbers of stents. *Gastrointest Endosc* 2001;54:162-8.
- [12] Cote GA, Kumar N, Anstas M, Edmundowicz SA, Jonnalagadda S, Mullady DK, et al. Risk of post-ERCP pancreatitis with placement of self-expandable metallic stents. *Gastrointest Endosc* 2010;72:748-54.
- [13] Colton JB, Curran CC. Quality indicators, including complications, of ERCP in a community setting: a prospective study. *Gastrointest Endosc* 2009;70:457-67.
- [14] Draganov P, Hoffman B, Marsh W, Cotton P, Cunningham J. Long-term outcome in patients with benign biliary strictures treated endoscopically with multiple stents. *Gastrointest Endosc* 2002;55:680-6.
- [15] Ginsberg G, Cope C, Shah J, Martin T, Carty A, Habecker P, et al. In vivo evaluation of a new bioabsorbable self-expanding biliary stent. *Gastrointest Endosc* 2003;58:777-84.
- [16] Lamsa T, Jin H, Mikkonen J, Laukkanen J, Sand J, et al. Biocompatibility of a new bioabsorbable radiopaque stent material (BaSO<sub>4</sub> containing poly-L,D-lactide) in the rat pancreas. *Pancreatology* 2006;6:301-5.
- [17] Tashiro H, Ogawa T, Itamoto T, Ushitora Y, Tanimoto Y, Oshita A, et al. Synthetic bioabsorbable stent material for duct-to-duct biliary reconstruction. *J Surg Res* 2009;151:5-88.